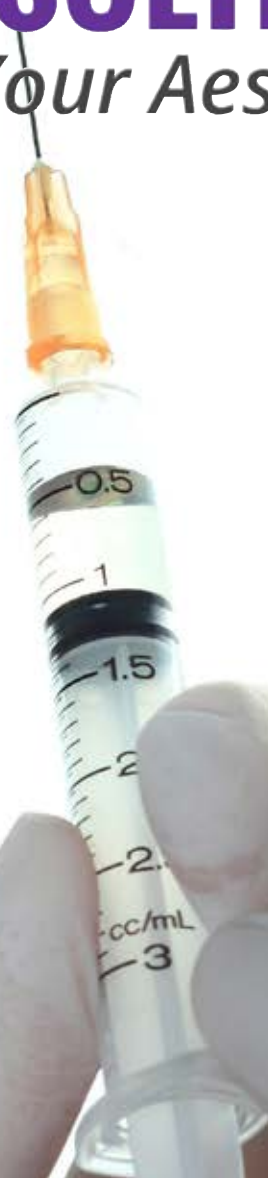



CONSULTING ROOM

Your Aesthetic Partner

CPD
CERTIFIED
The CPD Certification
Service
Collective Mark



FEATURE ARTICLE

Aspiration Before Dermal Filler Delivery...

Do you, or don't you?

ASPIRATION BEFORE DERMAL FILLER DELIVERY...

Do you, or don't you?



They say that there are only two certainties in life; death and taxes.

It's likely that the same certainty theory could be applied to aesthetic practice – *"if you inject enough dermal fillers, it is likely that you are going to have some type of vascular incident at some point"*; said American Dermatologist, Kenneth Beer, MD.¹

There are many best practices in place to minimise the risk of intravascular injections or vascular compromise, which could lead to embolism and necrosis; from using blunt-tipped micro-cannulas in place of sharp needles, to slow injection techniques and reduced bolus delivery of a filler product.

Being able to recognise the signs of an incident so that you can act quickly to mitigate any damage and stabilise the situation is paramount, but one of the best ways of avoiding vessel entry in the first place is said, by many, to be aspiration prior to injection.

Yet, it's not as cut and dried as that. There are arguments both for, and against, the practice; as well as the undue reliance upon negative aspiration prior to filler implantation. So much so, that many practitioners simply resign themselves to the 'better safe than sorry' argument; even if there is credible science to the contrary which should be

considered.

To that end, this article will look at the clinical data behind the 'to aspirate or not' debate, the views and opinions of some experienced aesthetic practitioners, and the results of a recently commissioned survey by Consulting Room to find out what is happening on the front line. This is combined with real-life examples of positive aspirations experienced in aesthetic practice.

How easy is it to aspirate?

Let's first look at the definition of aspiration...

In medical terms, it is usually used to describe the action or process of drawing breath. Much like we can suck in air to our lungs, so an empty syringe can do the same by the simple act of pulling back on its plunger to fill the barrel.

This simple mechanism of action has many practical applications in medical situations, from taking biopsies to abscess drainage, and in the practice of aesthetic medicine, it is often recommended prior to the delivery of a syringe full of dermal filler as a means of checking for blood aspirate which could relate to a compromised vessel. To many, this seems like a logical reason and argument to

support aspiration, yet it remains controversial.

There are many factors that will affect the ease with which one can even perform an aspiration test prior to filler delivery.

Things to consider include:

The design of the syringe.

This is unique to each manufacturer, and can impact on the ergonomic ease with which one can pull back or retract the plunger, to aspirate, without the plunger coming off. Many manufacturing companies have their plungers screwed into the mobile rubber tip to mitigate this occurrence.

The steadiness of your hand.

If your hand is moving, and the syringe is not stable and steady whilst attempting the aspiration, then the needle tip may simply cause blood related trauma in the tissues which presents as a false positive for a vessel entry. Similarly, it is also possible to pull back into a vessel that was initially skewered on entry, i.e. the vessel was initially punctured by the needle, and then passed through to a safe plane, but then during the aspiration check, the needle gets pulled back into the vessel thus delivering a positive aspirate, but by this point the needle is no longer in the intended plane for delivery so the test is flawed by instability of the syringe.

Whether, or not, the needle is primed or full of filler.

Priming the needle, or pushing on the syringe plunger until a small quantity of product extrudes from the end tip of the needle is not necessary for dermal fillers and not all practitioners routinely do it prior to delivery. Many 'old wives' tales are said to propagate regarding the risks of embolism, but as fillers are not being directly injected into the circulatory system, habitual needle priming, to remove the small amount of air present in the needle hub, is just that, habit. However, once the first injection of product is done and the needle moved to another location, then the needle becomes primed, by default, and this will mean that any drawback will have to include pulling back the product first before any blood aspirate.

The amount of negative pressure available.

With a full syringe of filler less negative pressure can be produced on retraction of the plunger. Less negative pressure means less drawback. As the contents of the syringe is used, thus it could be argued that the likely success of the aspiration technique is increased as more negative pressure is present. Similarly, the nature of the filler itself, how thick it is, for example, will impact on the increased forces required to create the negative pressure.

The viscosity, cohesivity or G prime of the product.

It is often quoted that attempting aspiration, particularly with a primed needle or after delivery of product on a previous injection, is not possible with all available products as the needle gets blocked and adequate draw back and suction through negative pressure is not achievable. Unlike other more commonly injected medical products, HA fillers have a gel-like consistency and this impedes the flow of blood back through it, unlike with more aqueous solutions. This is further compounded by highly viscous or thick gels, highly cohesive gels that want to maintain their form, and those with a high G prime or elasticity. The lower all of these characteristics are, the increased likelihood there is that blood could be drawn back through them. Therefore, consider the product that you are using and the impact it will have on your aspiration technique.

The depth and location of injection.

Depending on the depth of delivery for a specific filler product, and the indication, you will place the needle tip in varying depths of the dermal layers, and thus take into account the presence, or absence, of varying types of vascular structures. For example, superficial injections, such as those used in a mesotherapy or 'skin booster' style treatment, will be so shallow as to not risk encountering any blood vessels so aspiration is not needed. Similarly pushing the needle tip against the bone will impede the successful draw back for an aspiration test on a deep delivery.

“If you inject enough dermal fillers, it is likely that you are going to have some type of vascular incident at some point.”

The length of time you pull back on the syringe plunger.

Pulling back the plunger is one thing; but how long does one need to hold it for there to be an adequate time frame for any potential flashback blood to be visible to the practitioner? Too short a time given for this process may mean that filler within the needle, the intraluminal product, is not drawn back sufficiently to provide space and any potential positive flashback therefore never arrives and the result appears negative.

The speed with which you pull back on the syringe plunger.

Debate exists over the efficacy of the draw back depending on whether the plunger is pulled back slowly and steadily, compared to quickly and sharply.

Another issue is that a strong negative pressure created by pulling the plunger back too far, or too quickly, can cause small veins to collapse preventing withdrawal of any blood for the aspiration test, so a false negative result would occur.

The needle gauge.

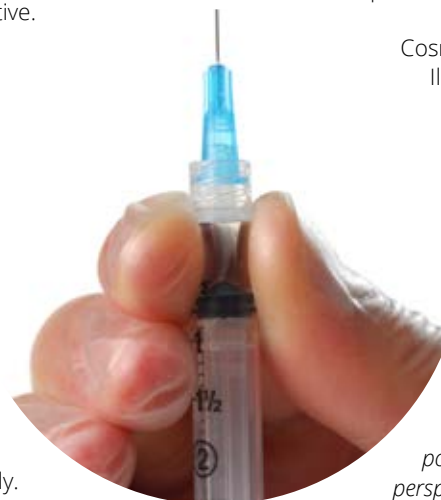The smaller the gauge of the needle, 30G compared to 27G for example, i.e. the thinner it is, the more potential there is for entry into the tiniest of blood vessels present in the dermal layers. Similarly, even with the use of blunt micro-cannulas there is the possibility of vessel puncture with the very thin gauged cannulas as they become more needle-like as they become thinner, thus aspiration may be advisable even though it is not a sharp needle. The needle gauge also impacts on the ease with which product (particularly thick ones) can be drawn up through it to allow for blood flashback. This is also a consideration in line with the internal bore of the needle, so called (ultra) thin-walled needles increase the flow of filler through smaller gauge needles which can help with otherwise tricky aspiration.

The needle length.

It stands to reason that a longer needle will take a longer time and increased force to achieve an aspiration test.

A bent needle.

The act of bending a needle to achieve a particular angle of entry for product delivery, sometimes used for non-surgical rhinoplasty for example, can impact on the forces at play when the syringe plunger is withdrawn and negative pressure applied, and can adversely impact the aspiration technique.



Cosmetic Doctor at Illuminate Skin Clinics, Dr. Sophie Shoter told us; *“I do routinely aspirate, regardless of whether the needle is primed. But I don't aspirate if I am working intradermally as there is no point from a safety perspective. I don't see*

a negative aspiration as a sign of safety though - I inject slowly, don't leave large boluses and keep the tip of my needle or cannula moving when appropriate, always watching for the sign of a problem".

"I always aspirate"; says Dr. Bhavjit Kaur, from Health & Aesthetic Clinic. "It is better to be safe than sorry. I agree that whilst injecting the needle can move, and that is the reason why I do not inject a filler volume of more than 0.05ml at one place, more than that could block the end arteries. The needle has to come out and I insert it again, aspirate and inject again. We must aspirate for at least 8 seconds, especially for high G prime fillers, if a flashback is to happen. Negative aspiration does not mean that you are not in the blood vessel, but positive aspiration alerts the injector. So, we have to aspirate to decrease the chances of injecting into a blood vessel."

Why should we aspirate?

In January 2014, a multi-national, multi-disciplinary panel of 16 experts in aesthetic medicine convened the *Global Aesthetics Consensus Group* to review the properties and clinical uses of hyaluronic acid fillers, with a focus on Hylacross® and Vycross® products from Allergan. From this they developed updated consensus recommendations for early and late complications associated with hyaluronic acid fillers.

The panel strongly recommended that clinicians aspirate with a needle or cannula before injection, especially in high-risk areas; however, they noted that; *"although positive aspiration is sufficient reason to remove the instrument and reposition, clinicians should not rely on negative aspiration to rule out the risk of intravascular injection"*.²

In a clinical paper³ published in April 2015 in *Clinical, Cosmetic and Investigational Dermatology*, Dr. Koenraad De Boule agreed with the need to aspirate and stated that; *"Before injecting, aspiration should be performed as a prophylactic measure, particularly in highly vascularised areas, and a new needle without filler used prior to deep bolus injections. Blood on aspiration indicates that the needle is in a blood vessel and the injection*

point should be altered. Injection must be performed slowly and with caution, allowing time to assess and react to any untoward response, changes in skin colour, or disproportionate pain."

Another well-known clinical paper on the subject is from Brazilian Dermatologist Dr. Gabriela Casabona, published in July 2015 in the journal of *Dermatologic Surgery*⁴.

During the study entitled, *'Blood Aspiration Test for Cosmetic Fillers to Prevent Accidental Intravascular Injection in the Face'*, a red ink solution was withdrawn from a cup using a syringe containing 0.1 ml of filler. The method assessed 17 different filler products using the manufacturer recommended or pre-packaged needles. When there was no positive aspiration, after 10 seconds, retesting was performed with larger-gauge needles until aspiration was observed. Products tested included HA ranges from Allergan, Galderma and Merz, as well as poly-L-lactic acid (Sculptra®) and calcium hydroxyapatite (Radiesse®).

Further to that, a selection of 5 filler products which had shown a positive aspiration in vitro were used in a white rabbit test. Aspiration was attempted after puncturing the ear vein and withdrawing the syringe plunger. The products tested were 3 HAs, the CaHA and the PLLA.

The results showed that the aspiration test with an ink solution in vitro was negative with 8 filler products (47%) and positive with 9 filler products (53%). For all the products that had a negative aspiration test, the test became positive when a larger-gauge needle was used. All 5 products tested with the rabbit ear aspiration test were positive.

Dr. Casabona therefore concluded that the aspiration test was reliable, with just over half of the syringes and needles tested proving positive results, and that adjusting the needle

gauge increased the reliability.

Why I routinely aspirate...

Cosmetic Doctor at MediZen Clinics, Consulting Room Advisor and Faculty Member of the Allergan Medical Institute, as well as Local Country Ambassador and National Complications Management Expert for Allergan, Dr. David Eccleston is a firm believer in the practice of aspiration prior to filler delivery.



He told me; *"I get fed up with those who insist that aspiration is a waste of time and a false reassurance. I would agree that the absence of a flashback of blood into the syringe on aspiration is not a guarantee that you are not in vessel, but equally, if you do get a flashback, it is confirmation that you are in vessel!"*

In my opinion, aspiration is only one of several precautions that should be taken, particularly in high-risk injection areas such as the medial and lower midface and the temporal area.

I have heard some say that aspiration is impossible with thicker products such as Juvéderm Voluma, but most of the aspirations I have seen in my practice have indeed been with Voluma, often in the second or third injection site with the same primed 27G needle. I have also seen positive aspirations with Juvéderm Volift and Volbella with a 30G needle fitted and primed.

In Australia, standard practice is not to aspirate, but to keep the needle moving as the injection progresses. The theory here is that if a vessel is indeed punctured, only a very small amount of product would enter the vessel before the needle has moved away. However, the counter argument to this is that constantly moving the needle may increase the risk of bruising.

There is no substitute for a detailed

three-dimensional injection anatomy knowledge on the part of the injector. Anatomy texts generally show the most likely location of a vessel based upon multiple dissections, but there is always variation within the norm.

For example, it is well described that Oriental types tended to have a much more medial location of the facial artery, whereas Caucasians usually have a more lateral location. This is one of the concerns I have about non-medical people injecting, as with the benefit of a one or two day injectables course, they cannot possibly learn anatomy in sufficient detail to become safe injectors. Furthermore, if something goes wrong, they are not in a position to recognise early signs of vascular damage, nor are they able to prescribe Hyaluronidase.

My view on aspiration is therefore that when using a needle, particularly in higher risk areas, aspiration should be considered mandatory. If vascular damage occurs and a legal case follows, I would feel most uncomfortable defending a colleague who had openly stated that he or she does not believe in aspiration, and it does not form part of their standard practice.

I would reiterate that aspiration is not a guarantee of safety if there is no flashback, as smaller vessels may collapse when aspiration is attempted, but it should represent one of several safety precautions when injecting. A steady hand is vital, as once aspiration has been performed, if the needle tip moves once injection has commenced, that aspiration has provided false reassurance as the needle may subsequently have entered a vessel. When using a cannula, the reality is somewhat different, as generally the cannula tip is kept in constant motion in order to provide a 'field effect' with the filler.

Furthermore, as I am a secondary referral centre for HA filler related

complications, my personal practice has shifted so that I now use exclusively hyaluronic acid fillers, and have ceased using any particulate non-HA fillers. These products may produce excellent cosmetic results, but in cases of intravascular injection, there is no benefit from hyaluronidase and therefore results can be catastrophic."



Cosmetic Doctor at Bright New Me and Chair of the Trafford Division of the British Medical Association, Dr Sarah Norman is also an advocate for aspiration.

"I like needles as I am confident in my steady hand. I also like to be sure where the tip of the needle is. To my knowledge, the use of a cannula does not prevent the risk of an intravascular injection. I therefore have not, to date, felt the need to use cannulae. I do, however, intend to keep an open mind and regularly refresh my knowledge.

I inject no more than a 0.1ml bolus, and I have a low bruising rate, due to a combination of slow injection, the use of arnica and ice, 60 seconds of pressure applied on any bleeding point, fresh pineapple advice⁵ and Vitamin K cream. I inject slowly and aspirate for 5-6 seconds in the highest risk areas, e.g., the zygomatic arch, top of the nasolabial fold and glabella, and about 4 seconds in lower risk areas.

In the last 5 years, I have had at least one flashback per year, mostly at the zygomatic arch CK1/ L1 site. The flashback has always appeared within a second or so - almost immediately. I only use the Allergan Vycross range, with the needles provided, which would appear to explain the prompt flashback.

I would like to draw practitioners' attention to the in vitro and in vivo study by Casabona in 2015 where some dermal fillers, using the needles provided, had a negative aspiration test. This study also highlights the risk of using fine gauge needles, even more so with some fillers than others.

I would always caution against total reliance on a negative aspiration test,

even using products such as those that I use, which are found to have a positive aspiration test time of 1-2 seconds. One always needs to have a healthy degree of wariness when undertaking a dermal filler procedure and observe for clinical signs of vascular occlusion. I also advocate limiting to 0.1 ml bolus maximum, as larger boluses carry a risk of extravascular occlusion.

I believe we should all advise our patients of the risk of vascular occlusion, verbally in advance and in the consent form. Patients should also have access to an emergency telephone number to use if necessary post procedure."

Why should we not aspirate?

I think it's probably fair to say that no one out there in the wider aesthetic community is stating categorically that you should not aspirate when delivering dermal fillers.

However, many do state that if you do not get blood visible in the hub or syringe when attempting it, this does not mean that you have eliminated the possibility of placing the product intravascularly, thus you cannot rely on aspiration (with a negative result) as a cast iron guarantee of safety, which begs the question, why do it?

A pivotal study which demonstrates this argument is a 2015 clinical paper from Canadian Dermatologist, Dr. Wayne Carey published in the Journal of Dermatologic Surgery⁶.

In the study, carried out alongside Dr. Susan Weinkle, entitled 'Retraction of the Plunger on a Syringe of Hyaluronic Acid Before Injection: Are We Safe?', they note that they both prefer using needles and do not aspirate before injecting HA syringes. They argue that aspiration is done, or routinely recommended, but is not evidence based and is mostly an historic adage.

They set up two studies to determine if, or when, blood could be withdrawn from a heparinised fresh tube of blood into the HA syringe.

They studied the complete range of product lines available from Allergan, Merz, Galderma and Teoxane.

Two different techniques were tested;

one using a slow-pull retraction of the plunger and up to a 5-second waiting time before release versus a rapid pullback and quick release.

Review of their findings showed that pulling back quickly with a short wait time before release, in most cases does not allow for sufficient removal of the intraluminal filler from the needle which would allow the return of blood, leading to false negative results.

They conclude that a slow, gentle, but firm withdrawal of the plunger in a linear non-accelerated manner is essential if the practitioner is attempting to check for intravascular placement of the needle. By maintaining a maximum negative pressure for a prolonged waiting period, it may release the material and allow for the return of blood.

They also noted that when the test brings back no blood from the test tube, by replacing the HA-loaded needle with a HA-free needle of the same gauge or even smaller, one can then readily withdraw blood into the HA-containing syringe in all cases.

They concluded that this clearly demonstrates that the ability to withdraw blood into the syringe requires the needle lumen or hub to be cleared of HA. The viscosity of blood or the material in the syringe itself plays no role they state.

More and more automated needle delivery systems are now coming to market and these do not allow the practitioner the freedom to aspirate prior to injection.

The use of such devices was covered in a previous feature article entitled **Are you missing the point? The Evolution of Syringes & Injectable Delivery Systems.**

The manufacturers of these devices often quote the Carey and Weinkle paper as justification for their use of controlled flow rates, low pressure delivery and micro-boli extrusion as more efficacious for the avoidance of intravascular compromise, as the devices do not permit aspiration.

Why I don't routinely aspirate...

Plastic Surgeon, and Consulting Room Advisor, Mr. Niroshan Sivathasan believes that the importance of aspiration is often over-exaggerated; but that is not to say that one should not aspirate.

He explained; *"Aspiration is NOT a reliable indicator of intravascular entry, and the emphasis on aspiration pre-delivery of fillers is, in my strong opinion, blown way out of proportion. The calibre and collapsibility of facial vessels results in very limited efficacy of aspiration, and, of course, the anatomical area of injection is also a factor, albeit to a lesser extent, that practitioners must consider when injecting fillers.*

The very limited benefit of aspiration essentially depends on five factors, as deduced by physics and common sense:

1. *Viscosity of the filler (less so, if the needle is 'not' primed);*
2. *Gauge of needle (e.g., 25G vs. 31G);*
3. *Duration of aspiration (e.g., 10 seconds);*
4. *Steadiness of syringe-holding hand during aspiration – it is possible to re-enter a vessel during the small movements that occur during aspiration;*
5. *Depth of placement (e.g., the immediately pre-periosteal and the intradermal zones do not have any vessels).*

Lastly, even when aspiration is attempted, one cannot be sure that the blood that has travelled up the needle has not been from blood that is consequential to trauma locally at a more superficial level, and one must also remember that in many cases, the hubs of needles are small and so blood may not easily be seen – this false negative may falsely reassure the practitioner, who may then exercise a higher

threshold for concern in the presence of suggestive signs or symptoms. Human nature is, after all human nature.

I also believe that if a reasonable amount of filler has already been placed locally, particularly as boli in less-elastically forgiving areas, then it is possible that surrounding blood vessels may be extraneously compressed to some degree. This means that the amount of blood flow in those vessels in that immediate area is going to be reduced, which hence means that the alleged value of aspiration has to be lower.

The risk of intravascular delivery is most certainly possible, but its occurrence is very rare. Whilst aspiration may very occasionally exhibit the flashback of blood, ultimately, to avoid vascular compromise, the best approach is to have a considered rate of injection (avoid aggressive, high-pressure, high-rate injections), limit the size of boli (to prevent the external occlusion of a vessel by compression), and, of course, knowledge of the location of vessels (with recognition that significant variation may occur, and therefore to be sensitive to concerning signs and symptoms of vascular embarrassment). In my practice, I typically use larger cannulae for high-risk areas (e.g., medial periorbital zones) to increase the safety-margin."



What is happening in practice?

With such a controversial subject matter, where conjecture is rife amongst both experienced and new practitioners in the aesthetic industry, it seemed only right to conduct a survey to discover what is happening on the 'shop floor' so to speak.

Consulting Room gathered data from 55 respondents. This breaks down as 25 aesthetic nurse independent prescribers, 17 cosmetic doctors, 9 aesthetic nurses, 3 cosmetic dentists and 1 cosmetic surgeon.

When asked about delivering dermal filler products into the face with a sharp needle, 65% said that they do routinely aspirate first. Only 7% said they do not, and 24% admitted to only doing it sometimes.

“No matter how much you know your anatomy, and practice safely, it can and does happen!”

When asked the same question in relation to using blunt-tipped micro-cannulas, only 29% said that they routinely aspirated before filler delivery, with 35% saying that they do not and 15% stating sometimes. The majority of comments noted the inability of the blunt tip, or cannula gauge, to puncture vessels as the reason for deeming aspiration unnecessary with this device. 20% of respondents said that they do not use micro-cannulas in their practice so had no comment to make.

Of those who do regularly aspirate prior to injection, 92% stated that they do so every time that they re-enter an area to deliver product. Only 8% admitted to just doing so on initial entry. Comments noted that you could aspirate once on entry if depositing product in a retrograde manner, but should aspirate every time if re-entering or moving to deposit multiple boli of product.

When asked, what (multiple things) influence their decision to aspirate when using a sharp needle for filler delivery, 71% stated that they just always do it, no matter what, as you simply never know. A further 39% noted the area of the face that they are injecting into, and 33% the dermal plane that they are targeting. Thickness of filler or the needle gauge was only a consideration by 10% of respondents.

One independent nurse prescriber said; *“Aspiration before any injection has been ingrained into my practice as a nurse since training. I feel it is a good practice to have... what’s the harm of doing so?”*

“I had a vascular occlusion on the lower lip where I had aspirated for 10 seconds and had no flash back. Only once luckily. I would recommend that each, and every, practitioner carries Hyalase® and ensures their clients are fully aware of the risks, as rare as they are. No matter how much you know your anatomy, and practice safely, it can and does happen!”; stated another aesthetic nurse.

58% of respondents also agreed that they ‘just do it’ when using micro-cannulas for the same reason that you never know when a compromise might happen. The gauge of the micro-cannula was a more important factor for aspirating with this technique with 15% saying that influenced their decision whether to aspirate or not, and 10% also took the tip shape (domed or tapered) into account.

“I have seen flashback when using cannula. It can definitely happen!”; said one respondent.

It’s clear that many respondents choose to aspirate, but we felt it was important to further question techniques used in practice to try and establish a norm.

We asked how long practitioners were holding back the syringe plunger during an aspiration check. 48 people responded to this question.

10 people said they held it for 2 to 3 seconds, 2 said 3 to 5 seconds, 17 (35%) said around 5 to 7 seconds and about a third, 17 people, stated 8 to 10 seconds. Two people reported that they have recently changed their practice and now maintain the hold for longer, following advice or noting the experience of others.

As noted in the clinical paper from Dr. Carey et al, the rapid pull and release technique is significantly less effective in demonstrating blood withdrawal, especially with cohesive HA materials.

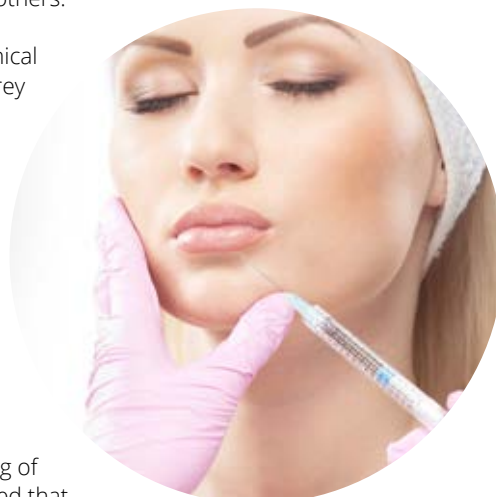
Further questioning of those who answered that they do not routinely aspirate

when performing filler injections found some interesting explanations for their decision. These included:

- Not being trained to aspirate prior to practice; a learning discrepancy which some felt they should now address.
- Deeming the aspiration test to be inadequate. This was due to the slightest movement placing you in a ‘new’ area, thus a feeling of having no confidence whether you’re in or out of a vessel; before, during or after aspiration.
- Limited or poor evidence to support it in practice and a claim that it produces too many false negatives.
- Choosing to inject very slowly, instead of aspirating, and to watch for a problem. The knowledge that only a very small amount of product has been released before spotting that you have hit a vessel was felt to be more practical.

Should a positive flashback occur, most survey respondents agreed that they would withdraw the needle, apply firm pressure to the area for a minute, remove and discard the contaminated needle, extrude enough product from the syringe to remove the blood, attach a new needle, and approach another entry point ready to aspirate and inject once more.

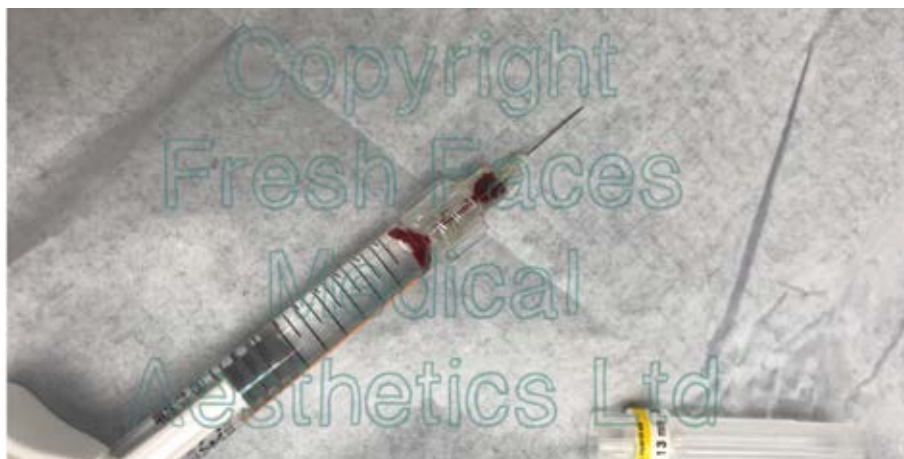There are no issues with the continued use of the product, but the blood must be removed to avoid causing inflammation upon its reinjection, felt many.



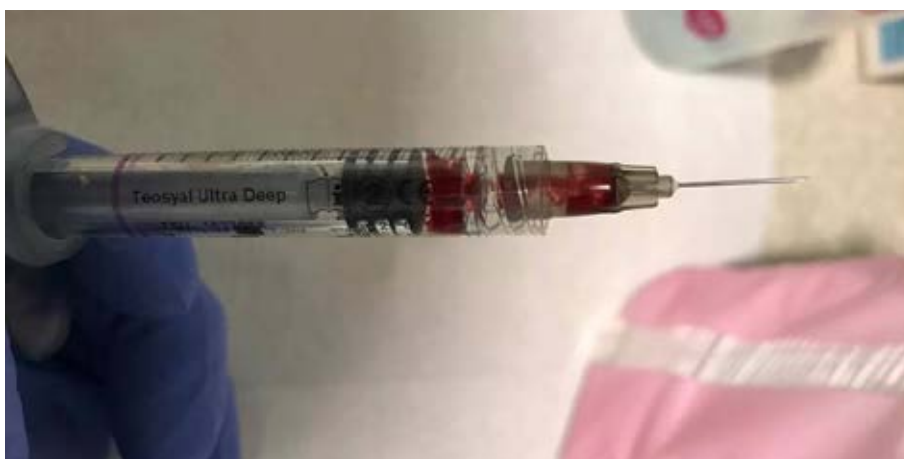Examples of Positive Aspiration



*Photo provided courtesy of Dr. David Eccleston from MediZen Clinics.
Juvéderm Voluma with a 27G needle in the midface, after priming the needle, and after two injections.*



*Photo provided Courtesy of Helen Blanchard, RGN, NIP from Fresh Faces Medical Aesthetics Ltd.
I was treating a forehead, having marked carefully all my zones for safe placement of product, knowing the approximate position of supratrochlear and supraorbital arteries, and taking steps to avoid them. Injecting onto the periosteum with Belotero Balance, using a 30 gauge needle, I aspirated for 10 seconds. As I got to 9 out of 10 there was a significant flash back.*



*Photo provided courtesy of Dentist, Dr. Martina Collins from Martina Collins Dental & Skin Clinic.
I've been injecting for 11 years and today for the first time I got a flashback of arterial blood using a 27G needle in CK1 (zygomatic arch) using Teosyal Ultra Deep.*

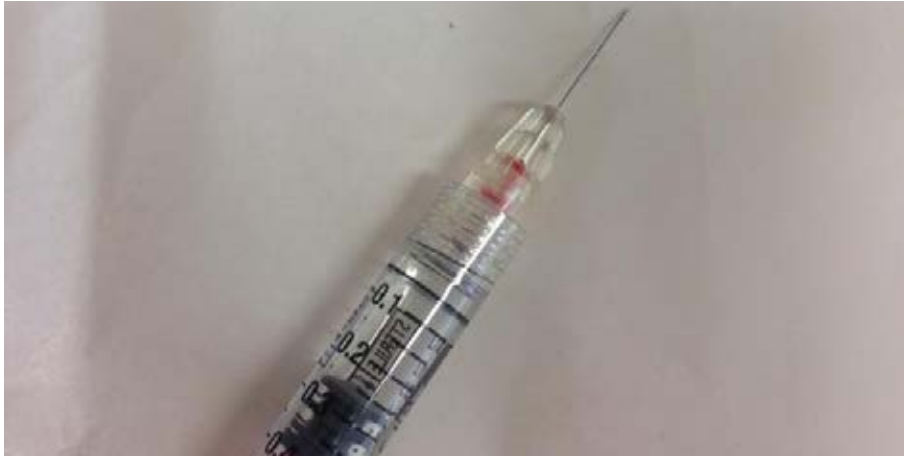

Photo provided courtesy of Dr. Bhavjit Kaur from Health & Aesthetic Clinic.

Treating the lateral aspect of the tear trough, the outer aspect of eye, with Juvéderm Volbella using a 30G needle, as sometimes using a blunt cannula you cannot reach the area.

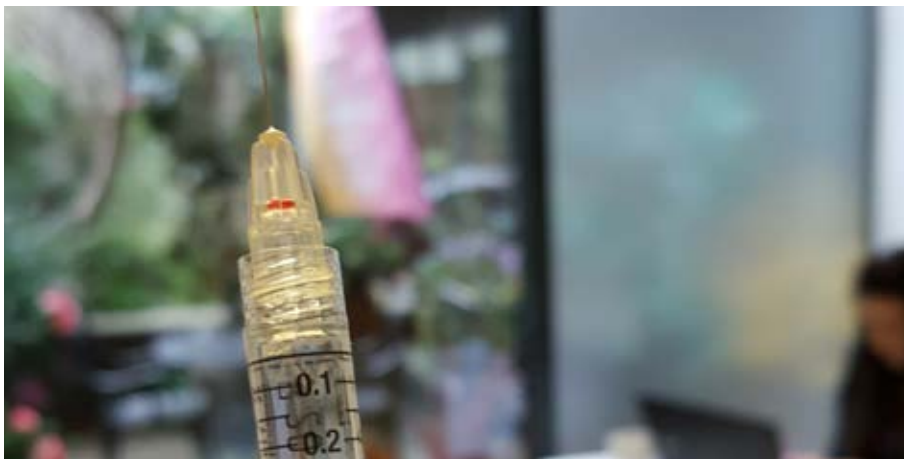

Photo provided courtesy of Dr. Tim Pearce, Medical Director at SkinViva Training.

This proves a positive result in a situation with several variables that would make a positive aspiration less likely. It's a thick product (Juvéderm Voluma), with a thin needle (31G), and it has already been primed and used for one previous injection.

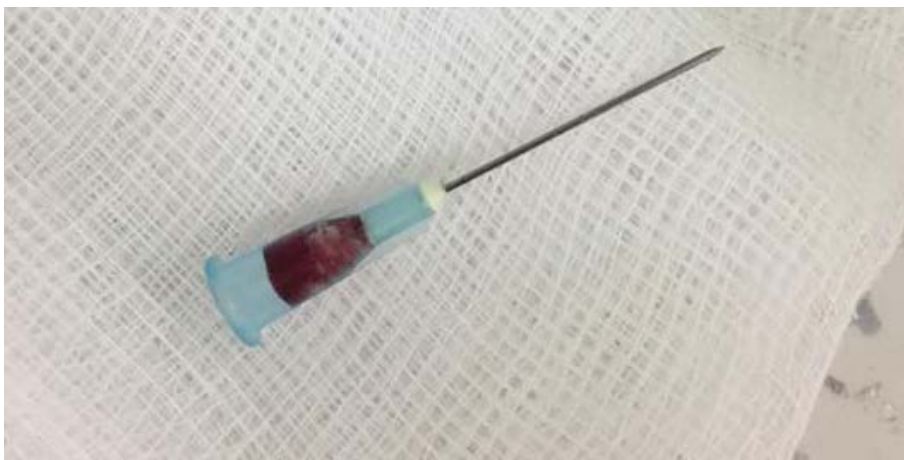

Photo provided courtesy of Andrea Curtis RGN, NIP from Face Kandi.

This happened to me today, for the first time in 7 years. Using Perfectha Subskin in the cheek for a deep bolus. The client had taken aspirin the previous day for a headache.

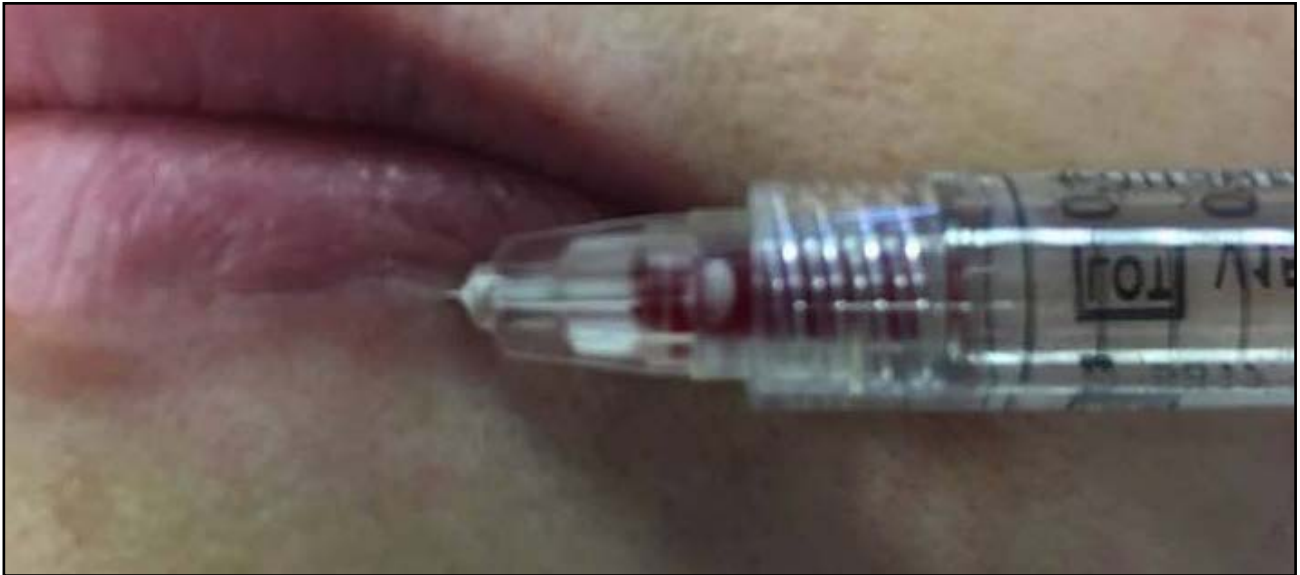

Photo provided courtesy of SkinViva Clinic.
 Treating the lips with a Juvéderm Vycross range product using a primed 30G needle.

Training

One survey respondent, an independent nurse prescriber plainly highlighted the issues for new trainees and the confusion that exists when they start practicing.

She stated; "I have started to aspirate when delivering periosteal filler and sometimes subdermal, due to the number of pictures of flashbacks I've seen recently. However, during many training sessions I've been taught that it takes a lot of aspiration force, and many seconds, to know if you're in a vessel, which doesn't sound quite right; but they were highly respected experts. I'd like further guidance/consensus opinion on this as I'm confused."

The requirement to learn the skill to correctly aspirate, as part of dermal filler delivery, is not explicitly mentioned within the published HEE report on qualification requirements⁷ for the dermal filler modality.

It does however note that there are learning and practice requirements for:

"in depth understanding of facial anatomy including relevant vessels, nerves, muscles and fat pads";

"knowledge of needle vs cannula technique, understanding of pros/cons and ability to use appropriately"; and

"recognition of specific severe adverse

events including vascular occlusion/ embolisation (which can lead to skin necrosis and scarring or permanent blindness) and expedient delivery of required emergency treatment".

All of this is therefore open to interpretation by training companies wishing to pass on best practice standards to new market entrants, or to accredit practitioners for prior learning skills. Therefore, some will teach aspiration, and some will not.

This is only of relevance if so called 'compliance' with the HEE recommendations is to be demonstrated to voluntary PSA accredited registers such as Save Face, Treatments You Can Trust and the Joint Council for Cosmetic Practitioners which will launch later this year. But, if the HEE don't mention aspiration then you could argue there is neither a requirement to learn it, nor to practice it. Yet, most reputable training companies still advocate teaching it.

Harley Academy, run one of only a handful of level 7 ofqual accredited cosmetic injectable training courses where students learn aspiration techniques from day one. They explain that their qualification is built around safety, and therefore they see aspiration as an added layer of protection, for both the patient and the clinician.

Managing Director, Dr. Tristan Mehta noted; *"We looked into this in depth, and our rationale for teaching aspiration was*

that 'the pros outweighed the cons'."

Dr. Sharan Uppal, Senior Trainer at SkinViva Training, who also offer an ofqual accredited level 7 certificate course in injectables, explained that given the potential consequences of intra-arterial dermal filler injections including blindness and necrosis of tissue, they think it is imperative to apply techniques that reduce these risks.

She said; "Aspiration prior to injection is a very quick and easy step that can reduce these risks. Many of the clinicians at SkinViva, myself included, have had positive aspirates. Had we gone ahead and injected in these cases, without aspirating we wouldn't have the low complication rates that we do. We encourage our trainees to make aspiration a matter of routine and shall certainly continue to do this in our practice."

The company also encourages a culture of celebrating positive aspiration results through their private Facebook group. They intend to change the mindset of practitioners so they realise that sharing such incidents with their peers benefits wider learning and the sharing of experience in practice and is nothing to be ashamed about.

Conclusions

Whether controversial or not, it simply comes down to what you feel comfortable doing. As medical practitioners, you have a duty of care

to know that you acted safely and in the best interests of your patients. To most this means that aspirating is one little, extra step in ensuring the safety of their patients. The notion that although it cannot be 100% fool proof, there is no harm in doing it seems to prevail.

Thankfully, we do have some, albeit limited, clinical evidence to draw upon. This provides further insight into what seems to be being confirmed by most in active practice, and certainly by the example images supplied to us as illustration for this article.

Dr. Casabona admits that aspirating may be limited in predicting the risk of intravascular injection, because the size and collapsibility of the facial vessels may be a limiting factor for the efficacy of aspiration in avoiding a vascular compromise. However, in her experience, the aspiration test is useful and reproducible. She maintains that with the proper gauge of needle being used, the most commonly used dermal fillers had a positive aspiration test in vitro and in vivo, which suggests that the aspiration test should be performed during a filler injection procedure regardless of location and depth.

Drs Carey and Weinkle agree somewhat, but also disagree, and point out that their study shows that in order to be 100% certain that blood is pulled back successfully, if the needle or cannula is intravascular, you would need to change the needle each time you injected a bolus with an HA-free, non-primed needle.

Although this would give you the guarantees that most practitioners are seeking, this method would be impractical. It would create a significant loss of product (and money) in the dead space of the discarded needle with each injection and new needle application.

Ignoring aspiration completely, they propose that practitioners look to other methods of avoiding a vascular compromise. Highlighting the accepted wisdom that more than 0.1ml needs to be injected intraarterially to cause significant injury, they advocate a slow, prudent "stop and go" technique which should limit damage. Embolisation can be recognised immediately in most cases, by an immediate whitening of the skin, and subsequent bluish hue, they state. Therefore, injecting rapidly under high pressure may result in larger amounts delivered intravascularly before action can be taken to stop the injection so slow and steady wins the race.

Yet, Carey and Weinkle appreciate that old habits die hard, so note that for those practitioners who wish to continue using

a pull-back technique of aspiration before injection, they recommend using a large bore needle, maximum negative pressure, fixation of the syringe position, and extended waiting time while the syringe is under negative pressure.

If aspiration prior to injection of dermal filler works for you, then clearly there is no harm in carrying on, but if you're not routinely aspirating, you need to be confident that you know and understand what you're doing and why.

Consulting Room would like to thank all the aesthetic practitioners who contributed their opinions, photographs and survey responses for inclusion in this article.

References

1. **Avoiding Complications with Fillers.** Kenneth Beer, MD. Volume 22 - Issue 11 - November 2014 (<http://www.the-dermatologist.com/content/avoiding-complications-fillers>)
2. **Global Aesthetics Consensus: Avoidance and Management of Complications from Hyaluronic Acid Fillers—Evidence- and Opinion-Based Review and Consensus Recommendations** (<https://www.ncbi.nlm.nih.gov/pmc/articles/PMC5242216/>)
3. **Patient factors influencing dermal filler complications: prevention, assessment, and treatment.** Koenraad De Boule and Izolda Heydenrych, On behalf of the Consensus Group. Clin Cosmet Investig Dermatol. 2015; 8: 205–214. (<https://www.ncbi.nlm.nih.gov/pmc/articles/PMC4404720/>)
4. **Blood Aspiration Test for Cosmetic Fillers to Prevent Accidental Intravascular Injection in the Face.** Casabona G. Dermatol Surg. 2015 Jul;41(7):841-7. (https://www.researchgate.net/publication/278731735_Blood_Aspiration_Test_for_Cosmetic_Fillers_to_Prevent_Accidental_Intravascular_Injection_in_the_Face)
5. Pineapple contains bromelain which is felt to help decrease bruising.
6. **Retraction of the Plunger on a Syringe of Hyaluronic Acid Before Injection: Are We Safe?** Carey, Wayne MD, FRCP(c), Weinkle, Susan MD, FAAD Dermatologic Surgery: December 2015 - Volume 41 - Issue - p S340–S346 (http://journals.lww.com/dermatologicsurgery/Fulltext/2015/12001/Retraction_of_the_Plunger_on_a_Syringe_of.10.aspx)
7. **PART ONE: Qualification requirements for delivery of cosmetic procedures: Non-surgical cosmetic interventions and hair restoration surgery.** Health Education England. November 2015 (<https://hee.nhs.uk/sites/default/files/documents/HEE%20Cosmetic%20publication%20part%20one%20update%20v1%20final%20version.pdf>)



Lorna Jackson, BSc.

Lorna has been Editor of Consulting Room, the UK's largest aesthetic information website since 2003. She has become an industry commentator on a number of different areas related to the aesthetic industry, collating and evaluating statistics, plus researching, investigating and writing feature articles, blogs, newsletters and reports for Consulting Room and various consumer and trade publications, including Cosmetic News, Journal of Aesthetic Nursing, Body Language, PMFA News, Aesthetic Medicine and Aesthetic Dentistry Today. Lorna has also been asked to present at various industry events, including Smart Ideas, FACE and the CCR Expo. She was awarded Journalist of the Year at the MyFaceMyBody Awards 2014.





CPD
CERTIFIED
The CPD Certification
Service

*The content of the following has been certified by the
CPD Certification Service
as conforming to
continuing professional development principles.*

Article:
Aspiration Before Dermal Filler Delivery...
Do you, or don't you?

CONSULTINGROOM.COM
(1376)

Date:

April 2017

Certificate No:

A006389